Managing complications of ileal conduits in primary care

Jonathon Carll, Peitong Li, Keane Henderson, Kathy Kong, Nathan Lawrentschuk

Background
Ileal conduits are an uncommon form of stoma that are formed by urologists to create permanent urinary diversion. Almost all ileal conduits are created in patients who have had their bladder removed for malignant or functional reasons. However, it is a highly morbid procedure with reported complication rates as high as 63%.

Objective
The aims of this article are to provide an overview of ileal conduits as well as common issues and complications general practitioners (GPs) may encounter, and to improve care for patients with ileal conduits.

Discussion
Ileal conduits are the most common form of permanent urinary diversion, usually performed after radical cystectomy for bladder cancer. Both early and late complications are common and require multidisciplinary management and close coordination within the care team.

AN ILEAL CONDUIT is a form of permanent incontinent (free-draining) urinary diversion created for patients who no longer have a functioning bladder, most commonly because of surgical removal (cystectomy), although a minority of patients will have a conduit created for palliative or functional reasons and have their native bladder left in situ.[1] The vast majority of ileal conduits are performed at time of radical cystectomy done for bladder cancer, although cystectomy may be performed for benign conditions such as neurogenic bladder, radiation cystitis or interstitial cystitis/bladder pain syndrome.[2]

An ileal conduit is created by harvesting a short segment of ileum (with the terminal ileum preserved for vitamin B12 absorption[3]) that is re-anastomosed to restore bowel continuity (Figure 1). The ureters are anastomosed into the proximal conduit over a ureteric stent to reduce urine leaks and strictures,[4] and the distal end is brought out as a pouting stoma to protect the surrounding skin from urine (Figure 2). Ureteric stents are usually removed 10–14 days postoperatively. Although conceptually simple, radical cystectomy is a high-morbidity procedure, with a 30-day complication rate

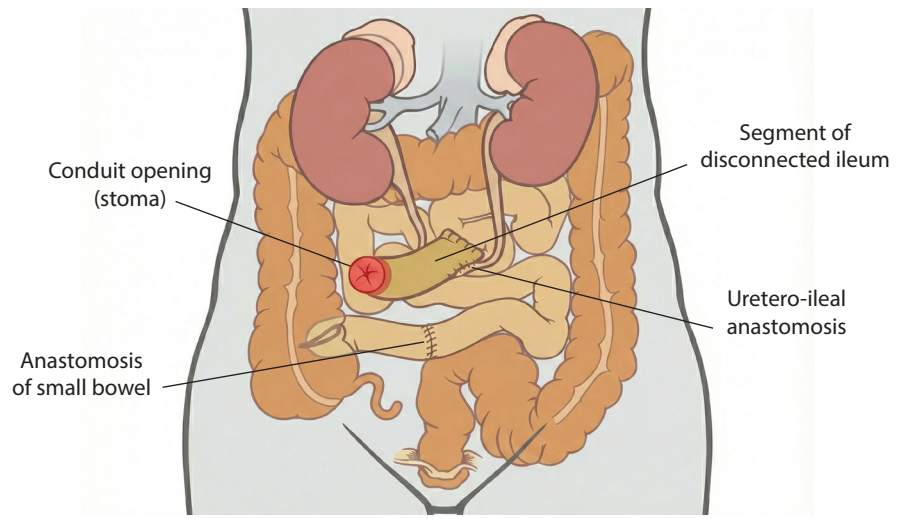

Figure 1. Simplified anatomical diagram of an ileal conduit.

© The Royal Australian College of General Practitioners 2026

approaching 50%[5] and frequent long-term complications (up to 66%).[6] As a result, many patients will present to primary care with postoperative or chronic issues requiring coordinated care with stomal therapy nurses, urologists, oncologists and psychological support services.

Complications of ileal conduits

Stomal complications

Like any stoma, an ileal conduit can have many local complications, affecting up to 24% of patients (Table 1).[6] Complications can be primary, or secondary to poorly fitting stoma devices. This includes

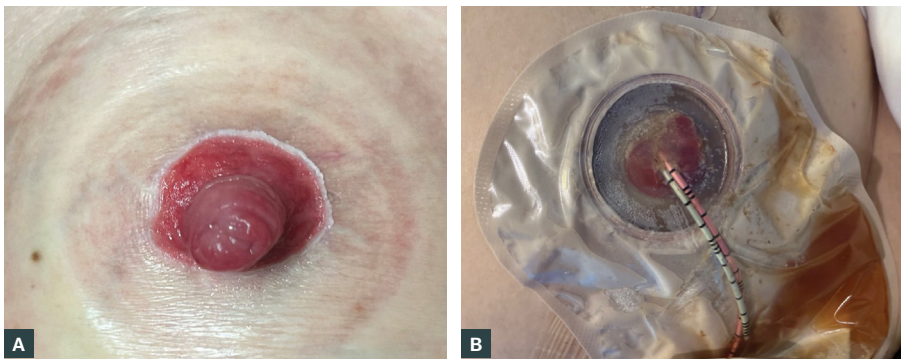

Figure 2. Appearance of healthy ileal conduits. **A.** A healthy pouting ileal conduit. **B.** A new postoperative conduit with ureteral stents in situ.

Table 1. Appearances of various stomal complications

Condition		Features	Management
Necrotic conduit (stents in situ postoperatively)		• Dark or dusky mucousa • Can be painful • Normal urine output	• Urgent referral to urology • May need conduit revision • Some can be managed conservatively
Allergic contact dermatitis to stoma device or adhesive		• Localised reaction in area of stoma plate • Red, swollen, itchy	• Referral to stomal therapy • Can trial alternative device • Topical steroids
Irritant contact dermatitis		• Urine leaking around stoma device • Red, macerated skin in areas in contact with urine	• Referral to stomal therapy • Review device and ensure it fits appropriately • Barrier spray to affected skin
Ulceration from pressure wound	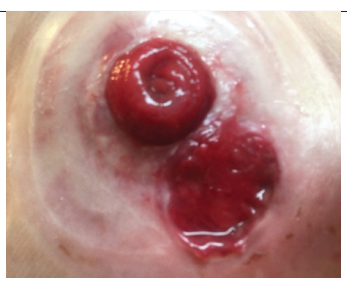	• Tightly fitting stoma device • Chronic irritation from urine • May be secondary to parastomal hernia and hernia belt	• Referral to stomal therapy to change device to one with less pressure • Hydrocolloid gel with alginate • Calcium alginate dressing

Table continued on the next page

© The Royal Australian College of General Practitioners 2026

Table 1. Appearances of various stomal complications (cont'd)

Condition		Features	Management
Retracted conduit		• Not pouting • Mucousa below skin level • Hypergranulation tissue may be present	• Referral to urology for consideration of revision • STN review to minimise leakage/skin contact with urine
Retracted and stenosed conduit		• Narrow opening • Stoma opening retracted below level of skin • Minimal mucousa visible	• Referral to urology for consideration of revision • May need foley catheter insertion if obstructed
Parastomal hernia with skin ulceration		• Reducible/bulging mass next to stoma • May be difficulties fitting stoma because of hernia • Can result in urine contacting and irritating skin	• Referral to general surgery for hernia repair • Referral to STN to ensure device still fits conduit in interim

STN, stomal therapy nurse.

parastomal hernias, necrosis, and dermatitis from urine contact with the skin. This topic has been covered in detail by a prior paper in *Australian Journal of General Practice*,[7] so it will only briefly be touched on here with relevant clinical examples (Table 1). As with any stoma, should a patient present with complications, a thorough examination is an important first step in assessment (Box 1).

Metabolic complications

Acid–base disturbances can occur in ileal conduits, affecting up to 12.8% of patients.[8] Because urine passes quickly through the conduit with limited mucosal contact, metabolic complications are less frequent than in continent diversions. However, ion exchange across the ileal mucosa can still occur, leading to reabsorption of ammonium and chloride ions and secretion of bicarbonate into the urine, possibly causing a chronic hyperchloraemic metabolic acidosis. This contributes to bone resorption and increases fracture risk.[9,10] Patients with ileal conduits have a 48% higher age-adjusted fracture risk when compared with the general population,[10] so osteoporosis risk assessment and screening are advisable.[11]

The most common types of utereroenteric anastomosis are the refluxing Bricker and Wallace techniques,[12] and the subsequent urinary reflux can lead to recurrent pyelonephritis and reflux nephropathy. Ultimately this places patients at high risk of

Box 1. Pertinent examination findings in a patient with an ileal conduit

- Colour of the conduit mucosa
- Whether the conduit is spouting or retracted
- Presence/absence of ureteric stents protruding from conduit
- Urine output
- Colour of urine
- Presence of any skin changes surrounding the conduit or beneath the stomal plate
- Presence of any palpable masses next to the conduit
- Presence of renal angle tenderness
- Presence of peritonitis/guarding on abdominal exam

© The Royal Australian College of General Practitioners 2026

chronic kidney disease, with a prevalence of up to 20%.[8] Therefore, patients should have their renal function and electrolytes monitored every 3–6 months after cystectomy for the first few years, and checked at least annually thereafter if stable.[13] Oral sodium bicarbonate or electrolyte replacement is often sufficient for treatment of any acidosis or electrolyte disturbances; however, referral to a renal physician should be considered if there is significant renal impairment or persistent electrolyte abnormalities, as per local referral guidelines.

Although effort is made to spare the terminal ileum during formation of the conduit, patients may still experience complications from vitamin B12 malabsorption, particularly if they have underlying bowel disease or prior small bowel resection. The terminal ileum is responsible for reabsorption of vitamin B12 and bile salts, so patients with ileal conduits are at risk of deficiencies, which can affect 14.6% of patients.[14] The US-based National Comprehensive Cancer Network recommends patients have their vitamin B12 levels checked annually as clinically indicated.[13]

Urolithiasis

Urolithiasis affects up to 9% of patients with an ileal conduit.[6] Chronic metabolic acidosis increases bone resorption and urinary calcium (hypercalciuria) while also reducing citrate excretion (hypocitraturia), removing a key inhibitor of stone formation.[15] The urinary environment in an ileal conduit – alkaline urine, low volume, chronic bacteriuria, and mucus from the bowel segment – favours calcium phosphate and struvite stone formation. Recurrent urinary tract infections (UTIs) with urease-producing bacteria further increase struvite stone risk.[15] Patients with conduits will experience similar symptoms to those with native bladders; obstructing ureteric stones will present with renal colic, whereas non-obstructing stones may be incidentally found on medical imaging. Non-obstructing stones 7 mm or larger should be referred to a urologist for consideration of elective treatment, whereas obstructing stones represent a medical emergency, and patients with ureteric stones should be referred to an emergency department for a urological review.

Infectious complications

Bacteriuria is a very common outcome of ileal conduit diversion, as the conduit is created from non-sterile small bowel tissue. The urine will be contaminated and colonised with a variety of micro-organisms in almost all patients.[16] Subsequently, there is no evidence that treatment of asymptomatic bacteriuria is beneficial in patients with ileal conduits.[16] However, because of this persistent colonisation, in addition to urinary reflux, patients with ileal conduits are at increased risk of pyelonephritis and urosepsis, affecting up to 23% of patients.[6] Use of antimicrobial therapy to treat bacteriuria in patients with ileal conduits should be limited to patients with symptomatic infections and patients with pyelonephritis or systemic infection (Table 2), as localised bacterial growth within the conduit will be asymptomatic.[17] Pyelonephritis presents similarly in patients with ileal conduits to those with normal bladders, with symptoms such as flank pain, haematuria and systemic symptoms such as fevers, nausea, rigors and raised inflammatory markers. Empirical treatment of such infections should be as per recommendations for pyelonephritis, as specific guidelines for patients with ileal conduits do not exist, and commonly cultured organisms include typical uropathogens such as *Escherichia coli* and *Enterococcus*.[16] For patients with recurrent episodes of pyelonephritis or systemic infection, preventive treatments for recurrent UTIs such methenamine hippurate can be trialled; however, there is a lack of evidence for these interventions in patients with ileal conduits.[16]

Table 2. Clinical presentation of important complications in ileal conduits

Complication	Clinical presentation
Symptomatic urinary tract infection	• Abdominal or flank pain • Nausea/vomiting • Fevers • Haematuria • Foul-smelling urine • Raised inflammatory markers • Systemic symptoms: lethargy, chills, sweats
Anastomotic stricture	• Often asymptomatic • Declining renal function • Hydronephrosis present on ultrasound • Urine output can be normal or reduced • Can lead to severe pyelonephritis/sepsis
Conduit obstruction	• Oliguria/anuria (decreased stomal output) • Acute kidney injury • Stomal complication likely to be present: retraction, stenosis or parastomal hernia • Abdominal pain localised to stomal site • Peritonitis/guarding (if obstruction has caused rupture of the conduit)
Renal colic	• Flank pain, radiating towards the groin • Renal angle tenderness • Fevers • Nausea/vomiting
Dislodged ureteric stent	• History of visible stent extruding from conduit (Figure 2B) • Patient-reported history of stent becoming dislodged accidentally, or extruding further than the normal 10–15 cm

© The Royal Australian College of General Practitioners 2026

Anastomotic strictures

Ureteroenteric stricture refers to a narrowing of the anastomosis between the ureter and a segment of bowel used in diversion. This can be due to either benign stricture at the anastomosis or a cancer recurrence at the anastomotic site.[18] It affects 3–10% of patients undergoing urinary diversion and is a substantial challenge for urologists.[19] It can cause obstructive uropathy, leading to hydronephrosis and decreased renal function. If this is associated with infection, it can lead to life-threatening infections and sepsis. Patients with an obstructed kidney and clinical evidence of infection such as fevers, tachycardia or pain warrant an urgent urological review. Initial management is to relieve the obstruction via a nephrostomy or ureteric stent, with definitive management often occurring later once the patient's condition is stabilised. A patient may require indefinite ureteric stenting if they are unfit for a definitive surgical repair of their stricture. These patients may present with a dislodged or extruded ureteric stent. This necessitates urgent urological review for replacement of their stent.

Conduit obstruction

Obstruction of an ileal conduit is analogous to acute urinary retention. It is caused by conduit complications such as parastomal hernias or conduit retraction/stenosis, leading to the conduit becoming obstructed and unable to drain urine. It is a medical emergency requiring de-obstruction. Emergency management involves placing a foley catheter into the conduit to relieve the obstruction. This can be safely attempted by a GP working in a rural or remote area where there are no surgical services available. A lubricated 16 or 14 French indwelling urethral catheter is placed through the conduit opening until urine is returned. The balloon is then inflated in a standard fashion. Should this be required, then urgent discussion with a urology service is required to organise immediate and ongoing care.

Haematuria

Visible haematuria in an ileal conduit requires urgent investigation and re-referral to a urologist. Possible causes include upper tract bleeding from a renal mass, kidney stones, a recurrence of the patient's bladder cancer in the ureter or renal pelvis,[20] or a secondary malignancy within the conduit itself.[20] Initial investigations should include urine cytology (three samples, labelled as ileal conduit samples, collected from the conduit bag mid-morning over 3 consecutive days) and contrast-enhanced computed tomography scan of the abdomen and pelvis, with both portal venous and a delayed intravenous pyelogram phase. The patient will likely require endoscopic evaluation of the urinary tract should these investigations fail to identify a cause.

Sexual and body image issues

When performed for treatment of bladder cancer, a radical cystectomy will typically also involve the excision of the prostate and seminal vesicles in males, and the removal of the uterus, ovaries and anterior vaginal wall in females.[21] Sexual dysfunction is common after surgery: males experience anejaculation and often erectile dysfunction, while females frequently report dyspareunia and reduced libido.[22] Pre-operative counselling and ongoing multidisciplinary support are essential. A permanent stoma can also affect body image and self-esteem.[23] Patients benefit from ongoing support and may require referral to psychologists and psychosexual therapists.

Conclusion

Patients who have undergone ileal conduit urinary diversion may experience a variety of stomal, metabolic, infectious, psychological and sexual complications from their surgery. Quite often these will present in the primary care setting because of limited availability and access to specialist urology services. Initial management of many of these conditions can be undertaken by primary care providers, although early investigation and onward referral are often warranted because of the complex needs of these patients.

Key points

- Asymptomatic bacteriuria is a common finding in patients with ileal conduits and does not warrant antimicrobial therapy.
- Obstruction of an ileal conduit is a medical emergency, and gentle insertion of a foley catheter is a simple and safe first management option.
- A dislodged ureteric stent requires urgent discussion with the local urology service.
- Patients with ileal conduits have complex needs and require multidisciplinary care.
- Sexual dysfunction and body image issues are common in patients who have had a radical cystectomy and ileal conduit.

Authors

Jonathon Carll MBBS (Hons), MSurg, Urology Registrar, Royal Melbourne Hospital, Melbourne, Vic; Research Fellow, EJ Whitten Centre for Prostate Cancer Research, Melbourne, Vic; The University of Melbourne, Department of Surgery, Melbourne, Vic

Peitong Li BSc, MD, Urology House Officer, Royal Melbourne Hospital, Melbourne, Vic

Keane Henderson MBBS, General Practice Registrar, Matraville Medical Complex, Sydney, NSW

Kathy Kong BSN, Grad Certificate Stomal Therapy, Clinical Nurse Consultant Stomal Therapy, Epworth Healthcare, Melbourne, Vic

Nathan Lawrentschuk MBBS, FRACS (Urology), PhD, Director, Royal Melbourne Hospital Department of Urology, Melbourne, Vic; Director, EJ Whitten Centre for Prostate Cancer Research, Melbourne, Vic; Professor, The University of Melbourne, Department of Surgery, Melbourne, Vic; Consultant Urologist, Peter MacCallum Cancer Centre, Melbourne, Vic

Competing interests: NL is a proctor for robotic surgery (Device Technologies Australia). All other authors have no competing interests to declare.

Funding: None.

Provenance and peer review: Not commissioned, externally peer reviewed.

AI declaration: The authors advise that there was use of artificial intelligence (AI)-assisted technology for assisting in the writing or editing of the manuscript, and accept full responsibility for all content. Details on how AI was used have been declared to the Editors in the cover letter.

Correspondence to:

jonathon.carll@icloud.com

References

References are available online only.

correspondence **ajgp@racgp.org.au**

© The Royal Australian College of General Practitioners 2026

References

1. Norus T, Fode M, Nordling J. Ileal conduit without cystectomy may be an appropriate option in the treatment of intractable bladder pain syndrome/interstitial cystitis. Scand J Urol 2014;48(2):210–15. doi: 10.3109/21681805.2013.840334.
2. Erpelding SG, Dugan A, Isharwal S, Strup S, James A, Gupta S. Cystectomy for benign disease: Readmission, morbidity, and complications. Can J Urol 2018;25(5):9473–79.
3. Duerksen DR, Fallows G, Bernstein CN. Vitamin B12 malabsorption in patients with limited ileal resection. Nutrition 2006;22(11–12):1210–13. doi: 10.1016/j.nut.2006.08.017.
4. Peng Y-L, Ning K, Wu Z-S, et al. Ureteral stents cannot decrease the incidence of ureteroileal anastomotic stricture and leakage: A systematic review and meta-analysis. Int J Surg 2021;93:106058. doi: 10.1016/j.ijsu.2021.106058.
5. Rezaee ME, Atwater BL, Bihrle W, Schroeck FR, Seigne JD. Ileal conduit versus continent urinary diversion in radical cystectomy: A retrospective cohort study of 30-day complications, readmissions, and mortality. Urology 2022;170:139–45. doi: 10.1016/j.urology.2022.08.020.
6. Madersbacher S, Schmidt J, Eberle JM, et al. Long-term outcome of ileal conduit diversion. J Urol 2003;169(3):985–90. doi: 10.1097/01.ju.0000051462.45388.14.
7. Finlay B, Sexton H, McDonald C. Care of patients with stomas in general practice. Aust J Gen Pract 2018;47(6):362–65. doi: 10.31128/AJGP-12-17-4430.
8. Shimko MS, Tollefson MK, Umbreit EC, Farmer SA, Blute ML, Frank I. Long-term complications of conduit urinary diversion. J Urol 2011;185(2):562–67. doi: 10.1016/j.juro.2010.09.096.
9. Domínguez García A, Muñoz Rodríguez J, Prats López J, et al. Why do patients with urinary diversions have an increased risk of bone fracture? A systematic review on risk factors for osteoporosis and bone mineral density loss in this group of patients. Actas Urol Esp (English edn) 2024;48(7):497–511. doi: 10.1016/j.acuroe.2023.11.009.
10. Richard PO, Bashir S, Riverin BD, et al. Risk of bone fractures following urinary intestinal diversion: A population based study. J Urol 2019;202(2):319–25. doi: 10.1097/JU.0000000000000213.
11. Ewald D. Osteoporosis – Prevention and detection in general practice. Aust Fam Physician 2012;41(3):104–08.
12. Davis NF, Burke JP, McDermott T, Flynn R, Manecksha RP, Thornhill JA. Bricker versus Wallace anastomosis: A meta-analysis of ureteroenteric stricture rates after ileal conduit urinary diversion. Can Urol Assoc J 2015;9(5–6):E284–90. doi: 10.5489/cuaj.2692.
13. Flaig T, Spiess P, Abern M, et al. NCCN Clinical practice guidelines in oncology: Bladder cancer. National Comprehensive Cancer Network, 2025. Available at www.nccn.org/professionals/physician_gls/pdf/bladder.pdf [Accessed 2 December 2025].
14. Ganesan T, Khadra MH, Wallis J, Neal DE. Vitamin B12 malabsorption following bladder reconstruction or diversion with bowel segments. ANZ J Surg 2002;72(7):479–82. doi: 10.1046/j.1445-2197.2002.02460.x.
15. Seth JH, Promponas J, Hadjipavlou M, Anjum F, Sriprasad S. Urolithiasis following urinary diversion. Urolithiasis 2016;44(5):383–88. doi: 10.1007/s00240-016-0880-y.
16. Qu LG, Adam A, Ranasinghe W, Lawrentschuk N. Systematic review: Bacterial colonisation of conduits and neobladders – When to test, watch, and treat. World J Urol 2020;38(6):1413–22. doi: 10.1007/s00345-019-02964-8.
17. Falagas ME, Vergidis PI. Urinary tract infections in patients with urinary diversion. Am J Kidney Dis 2005;46(6):1030–37. doi: 10.1053/j.ajkd.2005.09.008.
18. Westerman ME, Parker WP, Viers BR, et al. Malignant ureteroenteric anastomotic stricture following radical cystectomy with urinary diversion: Patterns, risk factors, and outcomes. Urol Oncol 2016;34(11):485.e1–485.e6. doi: 10.1016/j.urolonc.2016.06.008.
19. McNicholas DP, El-Taji O, Siddiqui Z, Hanchanale V. Systematic review comparing uretero-enteric stricture rates between open cystectomy with ileal conduit, robotic cystectomy with extra-corporeal ileal conduit and robotic cystectomy with intra corporeal ileal conduit formation. J Robot Surg 2024;18(1):100. doi: 10.1007/s11701-024-01850-9.
20. Yamashita R, Nakamura M, Notsu A, et al. Cumulative incidence and risk factors for recurrence of upper tract urothelial carcinoma in patients undergoing radical cystectomy. BJUI Compass 2024;5(5):483–89. doi: 10.1002/bco2.336.
21. van der Heijden AG, Bruins HM, Carrion A, et al. EAU Guidelines on muscle-invasive and metastatic bladder cancer. EAU Guidelines Office, 2024. Available at https://uroweb.org/guidelines/muscle-invasive-and-metastatic-bladder-cancer [Accessed 19 March 2025].
22. Milling RV, Seyer-Hansen AD, Graugaard-Jensen C, Jensen JB, Kingo PS. Female sexual function after radical cystectomy: A cross-sectional study. Eur Urol Open Sci 2024;70:142–47. doi: 10.1016/j.euros.2024.10.013.
23. Redeker C, Grunfeld E, Miles A. The impact of an ostomy on body image and sexual function of patients with colorectal cancer: A systematic review and meta-analysis. Psychooncology 2025;34(8):e70249. doi: 10.1002/pon.70249.

© The Royal Australian College of General Practitioners 2026