Merkel cell carcinoma: A case not to miss

William Luu, Matthew J Verheyden, Hui Yin, Paul Chee

CASE

A White man, aged 67 years, presented for a routine skin check. His history included multiple basal cell carcinomas and squamous cell carcinomas, eosinophilic asthma requiring long-term corticosteroids, and a family history of melanoma, placing him at moderate–high risk. There was a rapidly growing, asymptomatic 14-mm pink nodule on his left temple with mild central scale and a rim of induration (Figure 1), with no palpable regional lymphadenopathy. Dermoscopy revealed polymorphous, thick, tortuous vessels set against structureless milky pink–white areas, with slight central erosion but no pigmentation (Figure 2). Consequentially, a provisional diagnosis of Merkel cell carcinoma (MCC) was made. Differential diagnoses included amelanotic melanoma, squamous cell carcinoma, atypical fibroxanthoma and basal cell carcinoma.

Histopathology confirmed MCC, demonstrating small blue cells with hyperchromatic nuclei, minimal cytoplasm, and immunohistochemistry (IHC) was positive for AE1/3, CK20 and synaptophysin (Figures 3, 4). Tumour cells extensively infiltrated the dermis (Figure 4). Merkel cell polyomavirus (MCPyV) staining was negative (Figure 5). The patient was urgently referred to a multidisciplinary head and neck centre for staging and definitive management.

QUESTION 1

How common is MCC and what are the risk factors?

QUESTION 2

How is MCC diagnosed?

QUESTION 3

What is the prognosis of MCC?

QUESTION 4

What is the short- and long-term management for a patient diagnosed with MCC?

ANSWER 1

MCC is a rare neuroendocrine tumour with an estimated incidence of 2.5 per 100,000 in Australia, the highest in the world.[1]

Chronic sun exposure, older age (≥75 years), immunosuppression, male sex and fairer skin tones are risk factors.[1,2] Although MCPyV is the predominant etiopathogenetic factor in as many as 80% of cases in the Northern Hemisphere, ultraviolet radiation (UV) is the main etiopathogenetic factor in Australian cases of MCC.[2] In spite of its over-representation in the White population, cases have been reported in other ethnic populations with darker skin tones such as Asians and Pacific Islanders.[3]

ANSWER 2

Diagnosis of MCC hinges on a comprehensive skin and regional lymph node examination, histopathological evaluation of a biopsy showing sheets of small, round blue cells with scant cytoplasm, high mitotic activity and necrosis, and immunohistochemical confirmation – most notably a paranuclear 'dot-like' CK20 positivity combined with TTF-1 negativity – often supported by additional neuroendocrine markers, synaptophysin and chromogranin A.[3,4]

MCC typically presents as a rapidly enlarging, painless, erythematous or violaceous nodule on sun-exposed skin – most often the head and neck. Lesions on the trunk or extremities are less common, and mucosal involvement is rare. Although the majority of patients initially have localised



Figure 1. Clinical image of a 14-mm pink nodule on the left temple of the patient's head.

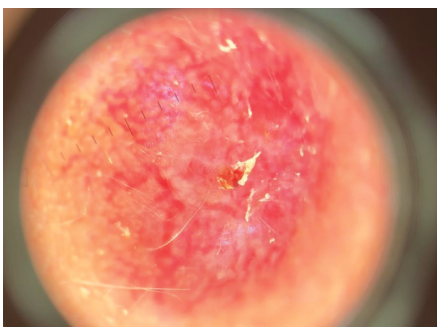

Figure 2. Dermoscopy image of the pink nodule from Figure 1.

© The Royal Australian College of General Practitioners 2026

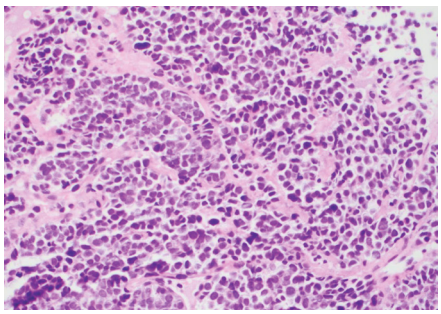

Figure 3. Tumour cells are small with hyperchromatic chromatin, inconspicuous nuclei and minimal cytoplasm, arranged in sheets and nests (haematoxylin and eosin staining, ×40 magnification).

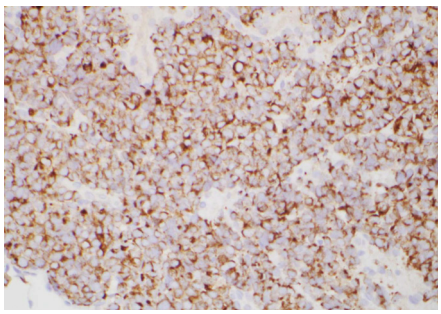

Figure 4. Tumour cells are positive for CK20 (characteristic for Merkel cell carcinoma, unlike other neuroendocrine carcinomas) (immunohistochemistry staining, ×40 magnification).

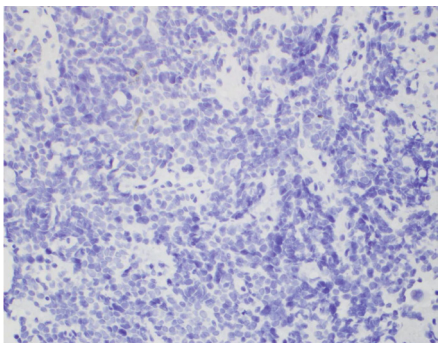

Figure 5. Tumour cells are negative for Merkel cell polyomavirus (immunohistochemistry staining, ×40 magnification).

disease, approximately 26% exhibit regional nodal spread and 8% present with distant metastases at diagnosis.[4]

A punch biopsy should not be delayed.

A simple A-E-I-O-U mnemonic can be helpful to remember during diagnosis: Asymptomatic; Expanding rapidly; Immunosuppression; Older than age 50 years; and UV exposure.[2]

Although there are no pathognomonic dermoscopy features, common descriptions in the literature include milky red hues with white areas and polymorphic arborising vessels.[3]

ANSWER 3

MCC carries a poor prognosis; the 5-year survival is approximately 51% for localised disease, which falls to approximately 35% once regional lymph nodes are involved, and drops <15% in the setting of distant metastases.[5] This is similar to Australian data where the median 5-year overall survival is approximately 46%.[6]

Underlying immunosuppression, male sex, head and neck primary tumours, and a lack of Merkel cell polyomavirus expression are associated with significantly reduced survival.[1,3]

ANSWER 4

In the short term, urgent referral to a multidisciplinary oncology team is essential. Baseline staging should include whole-body positron emission tomography-computed tomography (PET–CT) scan and sentinel lymph node biopsy to assess for clinically occult nodal and distant metastases.[4] Localised disease is managed with wide surgical excision plus adjuvant radiotherapy, whereas nodal involvement warrants complete lymph node dissection with radiotherapy. In metastatic disease, first-line therapy is anti-PD-L1 immunotherapy (eg avelumab), with cytotoxic chemotherapy reserved for second-line treatment.[4] Management follows European-consensus guidelines.[4]

In the long term, close monitoring is paramount. Approximately 90% of recurrences occur in the first 2 years, with recurrences possible in local or distant sites. Although no Australian guidelines exist, a practical follow-up schedule is every 3 months for the first 2–3 years, then every 6 months for the next 2–3 years. Progress PET-CT scans can form part of the monitoring process.[4]

CASE CONTINUED

Under the care of a multidisciplinary Head and Neck Oncology team, the patient completed definitive radiotherapy to the left temple MCC primary lesion. Interestingly, clinical and radiological evidence of metastases only became apparent following his radiotherapy. However, these metastatic nodules appeared to shrink without active treatment on progress PET-CT scans and a CT brain, chest, abdomen and pelvis scan. This phenomenon might be explained by a possible abscopal effect from his initial radiotherapy. He remains under ongoing surveillance for any disease progression.

Key points

- The aggressive metastatic potential and high mortality caused by MCCs require early suspicion and rapid diagnostic work-up by primary care physicians.
- Urgently refer suspected cases to a multidisciplinary oncology team for baseline staging and management.
- Follow patients closely; every 3 months for the first 2–3 years, then every 6 months for the next 2–3 years, incorporating interval PET–CT scans as clinically indicated.

Authors

William Luu BCom, MD, Senior Resident Medical Officer/Research Fellow, Dermatology Department, Westmead Hospital, Sydney, NSW

Matthew J Verheyden BSc (Biomed), MD, Advanced Trainee Registrar, Dermatology Department, John Hunter Hospital, Newcastle, NSW; Senior Clinical Lecturer, Sydney Medical School, The University of Sydney, Sydney, NSW

Hui Yin MBBS, MMed, FRCPA, Clinical Director Anatomical Pathology, Pathology Department, John Hunter Hospital, Newcastle, NSW

Paul Chee BMed (Hons), BMedSc, MMed, FACD, Head of Department, Dermatology Department, John Hunter Hospital, Newcastle, NSW

Competing interests: None.

Funding: None.

Provenance and peer review: Not commissioned, externally peer reviewed.

AI declaration: The authors confirm that there was no use of artificial intelligence (AI)-assisted technology for assisting in the writing or editing of the manuscript and no images were manipulated using AI.

Correspondence to:
wluu4879@uni.sydney.edu.au

References

References are available online only.

© The Royal Australian College of General Practitioners 2026

References

1. Mohsen ST, Price EL, Chan AW, et al. Incidence, mortality, and survival of Merkel cell carcinoma: A systematic review of population-based studies. Br J Dermatol 2024;190(6):811–24. doi: 10.1093/bjd/ljad404.
2. Walsh NM, Cerroni L. Merkel cell carcinoma: A review. J Cutan Pathol 2021;48(3):411–21. doi: 10.1111/cup.13910.
3. Coggshall K, Tello TL, North JP, Yu SS. Merkel cell carcinoma: An update and review: Pathogenesis, diagnosis, and staging. J Am Acad Dermatol 2018;78(3):433–42. doi: 10.1016/j.jaad.2017.12.001.
4. Gauci ML, Aristei C, Becker JC, et al; European Dermatology Forum (EDF), the European Association of Dermato-Oncology (EADO) and the European Organization for Research and Treatment of Cancer (EORTC). Diagnosis and treatment of Merkel cell carcinoma: European consensus-based interdisciplinary guideline – Update 2022. Eur J Cancer 2022;171:203–31. doi: 10.1016/j.ejca.2022.03.043.
5. Harms KL, Healy MA, Nghiem P, et al. Analysis of prognostic factors from 9387 Merkel cell carcinoma cases forms the basis for the new 8th edition AJCC staging system. Ann Surg Oncol 2016;23(11):3564–71. doi: 10.1245/s10434-016-5266-4.
6. Wang AJ, McCann B, Soon WCL, et al. Merkel cell carcinoma: A forty-year experience at the Peter MacCallum Cancer Centre. BMC Cancer 2023;23(1):30. doi: 10.1186/s12885-022-10349-1.

© The Royal Australian College of General Practitioners 2026