Table 1. Appearances of various stomal complications

Condition		Features	Management
Necrotic conduit (stents in situ postoperatively)		• Dark or dusky mucousa • Can be painful • Normal urine output	• Urgent referral to urology • May need conduit revision • Some can be managed conservatively
Allergic contact dermatitis to stoma device or adhesive		• Localised reaction in area of stoma plate • Red, swollen, itchy	• Referral to stomal therapy • Can trial alternative device • Topical steroids
Irritant contact dermatitis		• Urine leaking around stoma device • Red, macerated skin in areas in contact with urine	• Referral to stomal therapy • Review device and ensure it fits appropriately • Barrier spray to affected skin
Ulceration from pressure wound	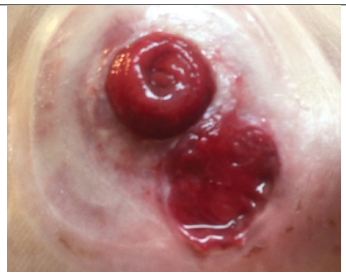	• Tightly fitting stoma device • Chronic irritation from urine • May be secondary to parastomal hernia and hernia belt	• Referral to stomal therapy to change device to one with less pressure • Hydrocolloid gel with alginate • Calcium alginate dressing
Retracted conduit		• Not pouting • Mucousa below skin level • Hypergranulation tissue may be present	• Referral to urology for consideration of revision • STN review to minimise leakage/skin contact with urine
Retracted and stenosed conduit		• Narrow opening • Stoma opening retracted below level of skin • Minimal mucousa visible	• Referral to urology for consideration of revision • May need foley catheter insertion if obstructed
Parastomal hernia with skin ulceration		• Reducible/bulging mass next to stoma • May be difficulties fitting stoma because of hernia • Can result in urine contacting and irritating skin	• Referral to general surgery for hernia repair • Referral to STN to ensure device still fits conduit in interim

STN, stomal therapy nurse.