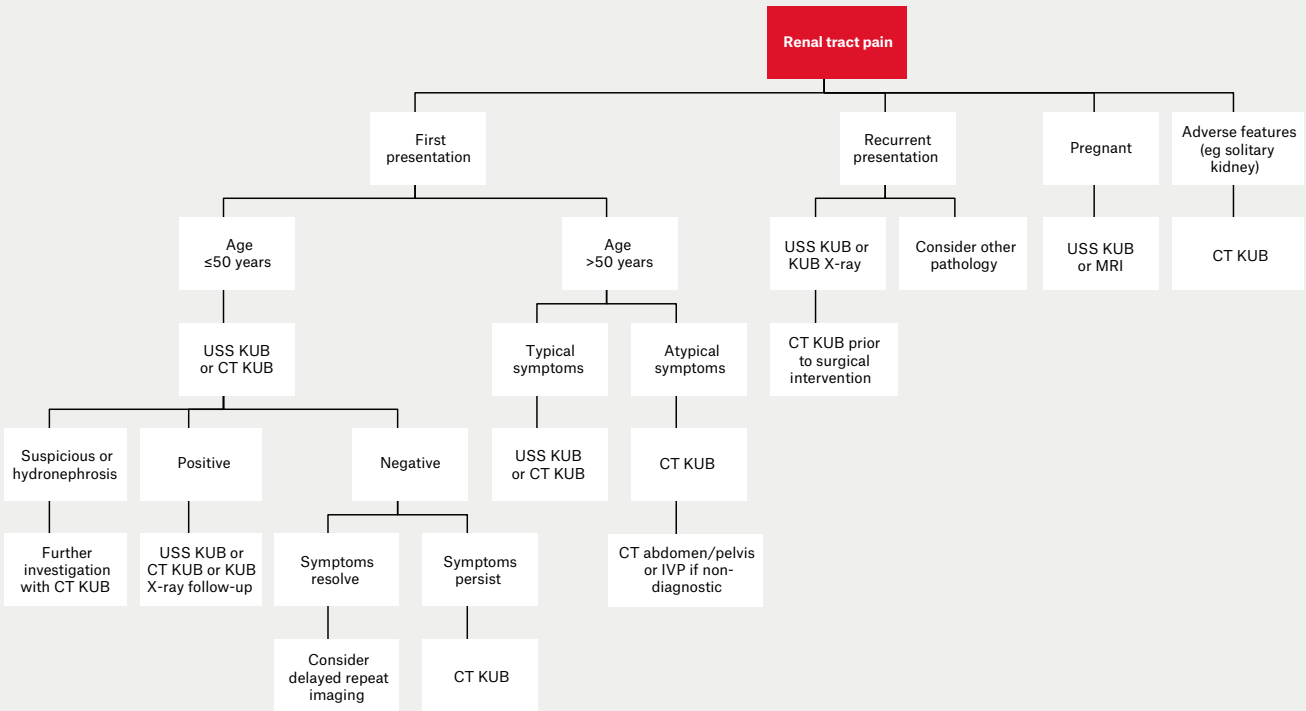

Figure 1. Diagnostic imaging pathway of renal tract pain[37]

CT, computed tomography; IVP, intravenous pyelogram; KUB, kidneys, ureters and bladder; MRI, magnetic resonance imaging; USS, ultrasonography

© The Royal Australian College of General Practitioners 2021